ISSN 2239-0634

Volume 2 - Number 3/2011

European Journal of Acne and Related Diseases

Official Journal of the Italian Acne Board

EJA

SCRIPTA MANENT EDIZIONI

Volume 2, Number 3/2011

EUROPEAN JOURNAL OF ACNE
AND RELATED DISEASES

Official Journal of the Italian Acne Board

EJA



Stefano Veraldi
Editor

Dear Colleagues,

Just a few words to introduce this 2011 final issue of the European Journal of Acne and Related Diseases.
The journal is becoming more and more international!
I am pleased to inform you that we set up an international board of colleagues.
They are, in alphabetical order:
Tam El Ouazzani (Casablanca, Morocco),
Marius Anton Ionescu (Paris, France),
Monika Kapinska Mrowiecka (Cracow, Poland),
Noppakun Noppadon (Bangkok, Thailand),
Gerd Plewig (Munich, Germany),
Robert Allen Schwartz (Newark, USA),
Jacek Szepietowski (Wrocław, Poland)
and Shyam Verma (Vadodra, India).
Furthermore, we are yet waiting for the answer of Egyptian, German, Slovenian, Swedish and Swiss colleagues.

Happy new year!

Cari Colleghi,

solo poche parole per presentare questo numero finale del 2011 dell'European Journal of Acne and Related Diseases.
Il giornale sta diventando sempre più internazionale!
Ho il piacere di comunicare che abbiamo costituito un board internazionale di colleghi.
Si tratta, in ordine alfabetico, di:
Tam El Ouazzani (Casablanca, Marocco),
Marius Anton Ionescu (Parigi, Francia),
Monika Kapinska Mrowiecka (Cracovia, Polonia),
Noppakun Noppadon (Bangkok, Thailandia),
Gerd Plewig (Monaco, Germania),
Robert Allen Schwartz (Newark, Stati Uniti),
Jacek Szepietowski (Breslavia, Polonia)
e Shyam Verma (Vadodra, India).
Inoltre, siamo ancora in attesa della risposta di colleghi egiziani, sloveni, svedesi, svizzeri e tedeschi.

Buon anno a tutti.

SCRIPTA MANENT EDIZIONI

Volume 2, Number 3/2011

EUROPEAN JOURNAL OF ACNE AND RELATED DISEASES

Official Journal of the Italian Acne Board

EJA

Editorial Board

Editor

Stefano Veraldi *Milano*

Co-Editor

Mauro Barbareschi *Milano*

Scientific Board

Vincenzo Bettoli *Ferrara*
Stefano Calvieri *Roma*
Gabriella Fabbrocini *Napoli*
Giuseppe Micali *Catania*
Giuseppe Monfrecola *Napoli*
Nevena Skroza *Roma*
Annarosa Virgili *Ferrara*

Managing Editor

Antonio Di Maio *Milano*

Content

Innate immunity and Toll-like Receptors modulation in acne *pag 65*
Marius-Anton Ionescu, Luc Lefeuvre

Treatment of steroid-induced rosacea-like dermatitis (SIRD) with azithromycin *pag 71*
Elena Guanziroli, Mauro Barbareschi

Short contact therapy of acne with tretinoin *pag 75*
Stefano Veraldi, Rossana Schianchi

Italian Acne Club

Mario Bellosta *(Pavia)*, Carlo Bertana *(Roma)*, Alessandro Borghi *(Ferrara)*, Francesco Bruno *(Palermo)*, Maria Pia De Padova *(Bologna)*, Paolo Fabbri *(Firenze)*, Carlo Pelfini *(Pavia)*, Mauro Picardo *(Roma)*, Maria Concetta Potenza *(Roma)*, Alfredo Rossi *(Roma)*, Patrizio Sedona *(Venezia)*, Aurora Tedeschi *(Catania)*, Antonella Tosti *(Bologna/Miami)*, Matteo Tretti Clementoni *(Milano)*

Editorial Staff

Direttore Responsabile: Pietro Cazzola
Direttore Generale: Armando Mazzù

Consulenza grafica: Piero Merlini
Impaginazione: Stefania Cacciaglia

Registr. Tribunale di Milano n. 296 del 01/06/2011.
Scripta Manent s.n.c. Via Bassini, 41 - 20133 Milano
Tel. 0270608091/0270608060 - Fax 0270606917
E-mail: scriman@tin.it

Abbonamento annuale (3 numeri) Euro 50,00
Pagamento: conto corrente postale n. 20350682
intestato a: Edizioni Scripta Manent s.n.c.,
via Bassini 41- 20133 Milano
Stampa: Arti Grafiche Bazzi, Milano

SCRIPTA MANENT EDIZIONI

È vietata la riproduzione totale o parziale, con qualsiasi mezzo, di articoli, illustrazioni e fotografie senza l'autorizzazione scritta dell'Editore.

L'Editore non risponde dell'opinione espressa dagli Autori degli articoli.

Ai sensi della legge 675/96 è possibile in qualsiasi momento opporsi all'invio della rivista comunicando per iscritto la propria decisione a:
Edizioni Scripta Manent s.n.c.
Via Bassini, 41 - 20133 Milano

EJA
European Journal of Acne and Related Diseases
Volume 2, n. 3, 2011

Marius-Anton Ionescu[1], Luc Lefeuvre[2]

[1] *Dermatology Polyclinic, Saint-Louis Hospital, Paris, France*
[2] *Laboratoires Dermatologiques d'Uriage, Courbevoie, France*

Innate immunity and Toll-like Receptors modulation in acne



Marius-Anton Ionescu

SUMMARY

BACKGROUND. *Toll-like receptors (TLR) are trans-membrane receptors part of the innate immune system. Defects in TLR pathway have the potential to lead to increased susceptibility to dysregulation and play a role in the pathogenesis of numerous inflammatory skin diseases (as seborrheic dermatitis, acne, atopic dermatitis). Toll-like receptor 2 (TLR2) can be activated by peptidoglycans from P.acnes structure, with a subsequent inflammatory cascade involving pro-inflammatory interleukins (IL-8) and inducing human beta-defensine 2 (hBD2) as one of the innate immune mechanisms of defense against microbes.*
PURPOSE. *We sought to assess the effects of a vegetal natural extract (Ombelliferae) associated with a long chain lipid (TLR2-Regul®) in ex vivo human skin in contact with P. acnes, focusing on the markers of TLR2 activation: expressions of IL-8 and hBD2. In a second step we assessed the effects of the same emulsion in a double blind clinical trial in a series of patients with light inflammatory acne.*
METHODS. *Normal human skin explants were treated by an emulsion O/W formulated with the complex TLR2-RegulTM (20 µl per explant) or by its vehicle (control). Extracts of P. acnes were added.*
The dosages of IL-8 (ELISA) and of hBD2 were performed at 24h. In a second part of this study was made a double blind clinical trial including acne patients with light inflammatory acne (2-3 IGA scale) using same O/W emulsion formulated with TLR2-Regul® (compared to its vehicle): 2 applications/day during 12 weeks. Were excluded patients having systemic or topical treatment for acne.
RESULTS. *P. acnes induced significant increase of IL-8 expression in all untreated skin explants. Skin explants previously treated by TLR2-Regul® in contact with P. acnes had a significant less important expression of IL-8 compared to control ($p<0.01$) and a significant increase of hBD2 expression ($p<0.01$).*
CONCLUSIONS. *In normal human skin explants in contact with microbial extracts, the expression of IL-8 (as main cytokine linked to TLR2 activation) was increased. In all skin explants treated by the complex TLR2-Regul® and exposed to extract of P.acnes, the expression of IL-8 was significantly down-regulated and hBD2 expression was significantly up-regulated. Results of the clinical trial showed in a series of 34 acne patients a significant decrease of IGA mean score (by 40%) in the group verum compared to the vehicle group (-24%)($p<0.05$). Larger clinical trials are ongoing in order to confirm the results of this pilot study focusing on the modulation of TLR2 in acne patients.*

Key words: *Toll-like receptor 2, IL-8, betadefensin hBD2, inflammatory acne.*

Introduction

The particular field that was subject of the highest award in medical research in 2011 underlined once again the importance of innate immunity and of *Toll-Like Receptors* (TLRs). This domain of medical research was opened more than 15 years ago by Nobel Prize recipients *Jules Hoffman* who discovered TLRs in Drosophila flyes[1] and *Bruce Beutler* that focused on the role of TRLs in mammals [2].

With the discovery of TLRs, the understanding of the innate immunity role was widened from the previously described *"nonspecific"* mechanisms - as the activation of complement and the phagocytosis - to the complex pathways of the TLRs activation and the subsequent expression of pro-inflammatory molecules and of anti-microbial peptides, subject of several recent studies.

This article presents in the first part *ex vivo* studies on TLR2 activation by *P. acnes* in human skin and its topical regulation by an association of a vegetal extract (*Ombeliferae*) with a long-chain lipid (TLR2-Régul®), then in the second part the results of a double blind, pilot clinical trial, using same topical formulation in a series of acne patients.

Toll-Like Receptors

The innate immune system is activated by complex mechanisms, among them TLRs are trans- membrane cellular receptors of human main *"interface"* tissues as skin, gastrointestinal tract and lungs. Skin TLRs are expressed by keratinocytes, Langerhans' cells, macrophages, monocytes and granulocytes. TLRs are activated by their contact with ligands from pathogen-associated molecular patterns (PAMPs) of microbes (bacteria, yeasts or viruses). Up today more than 11 types of TLRs were described [3, 4] (Figure 1).

TLRs have an extracellular domain (leucine) that is able to recognize ligands from microbes' structures, and an intracellular domain of the receptor for IL-1 and protein MyD88 Toll-IL-1R homology (TIR) from cytoplasm (Figure 2). The TIR domain participates to the induction of the cellular response (pro-inflammatory cytokines and antimicrobial peptides up- regulation). The binding process between microbe structures and TLRs' extracellular domain triggers a signal that initiates a succession of steps involving specific inflammation messengers, resulting in the release of various cytokines and defensines. Toll-like receptor 2 (TLR-2) is activated by 3 compounds of microbes as *P. acnes*. This will trig an inflammatory cascade involving mainly IL-8 (but also other cytokines as IL-1, IL-6) [3, 6].

Inflammatory response triggered by microbes as *P. acnes, S. aureus, Malassezias,* human papiloma viruses - HPV is linked to the activation of TLRs – especially in inflammatory diseases with microbial aggravating factors as acne, seborrheic dermatitis, atopic dermatitis [3, 5].

P. acnes-induced inflammation in acne is complex, a part of inflammatory pathway is due to TLR2

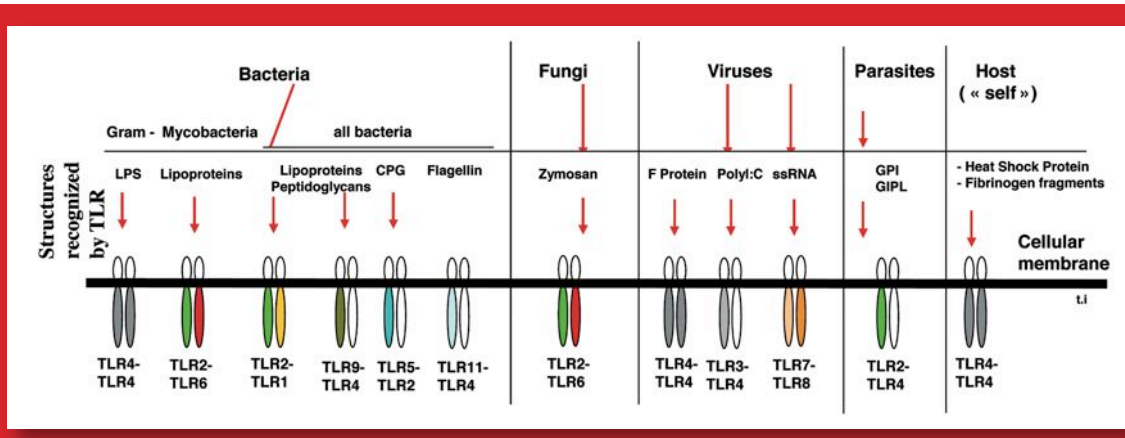

Figure 1. Structures recognized by TLRs (microbial and host).

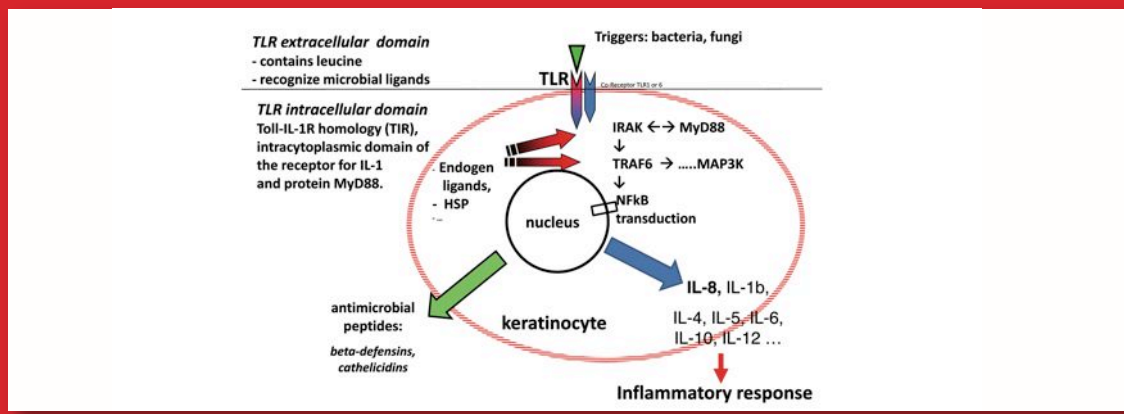

Figure 2. Toll Like Receptors – mechanisms of activation.

activation[3, 4]. Same receptor is activated in atopic dermatitis by *S. aureus* [3, 5], in leprosy [3] borreliosis / Lyme disease (ligands from *Borrelia burgdorferi*) [3, 5]. Yeasts-induced inflammation can be found in seborrheic dermatitis (linked to *Malassezias'* zymosan activating TLR2) and candidiasis (*Candida species* activate same TLR). *Papilloma viruses* from warts activate TLR7, and TLR8 [3,4].

In psoriasis TLR2, TRL7, TLR8, TLR9 are activated [4, 7]. In acne TLR participate to innate response to microbial presence: wall structure of *P. acnes* (mainly glyco-peptides) are acting as ligands and activate TLR2 (and TLR4) [8-14]. *P. acnes* activates TLR-2 and consequently induces the expression of IL-8 (and IL-6) within follicular keratinocytes, and of IL-8 and IL-12 within macrophages [13].

Sebocytes' and keratinocytes' antimicrobial peptides expression can be up-regulated, this being an important contribution to the innate immunity response within the pilo- sebaceous follicle. Changes of sebum lipids - as a modified ratio between different lipid fractions - induce alterations of keratinocyte in terms of differentiation and IL-1 secretion, leading to infra- infundibular hyperkeratosis and initiating first steps of micro-comedo induction. It has been shown that keratinocytes can respond to bacterial, fungal, and viral pathogens that have breached the stratum corneum by producing 2 important classes of endogenous peptides, beta-defensins and cathelicidins [10, 14]. Beta-defensin 1 is constitutively expressed, beta-defensin 2 (hBD2) is strongly up-regulated upon antigenic stimulation [10, 15]. In acne other factors can also increase hBD2 expression as free fatty acids from sebum [16].

TLR modulation in human skin [4]

We previously showed that in human skin in contact with microbial extracts the expression of IL-8 significantly linked with the activation of TLR2 [17,18].

We present here ex vivo tests on human skin assessing the modulation of TLR2 in presence of *P. acnes* with the focus on IL-8 and also on antimicrobial peptide expression hBD2.

An association of a natural vegetal extract (from the family of *Ombelliferae*) with a synthetic long-chain lipid (TLR2-Regul®) was tested on *ex vivo* human normal skin in contact with purified microbial extract of *P. acnes*.

The ***objective*** of this study was to assess the effects of the TLR2-Regul® on the expression of IL-8 – considering that this interleukin is not specific for TLR2 activation but is one of the main cytokines expressed after the activation of TLR2 in keratinocytes in contact with microbial extracts.3,4 This first test was followed by the assessment of antimicrobial peptide hBD2 expression in human skin in contact with *P. acnes* in the presence of same complex TLR2-Regul®.

Methods: skin explants A. were incubated (1 h at 37°C) in absence (control) or in presence of an emulsion O/W formulated with the complex TLR2-Regul® (20 µl per explant); B. at 1 h were added inactivated extracts of *P. acnes* (20 µl per explant); C. after 24 h incubation was performed the dosage of IL-8 (ELISA). Same steps A and B were used in order to assess antimicrobial peptides expression in human skin explants, in last step C. after 24 h incubation was preformed the dosage of human beta-defensin 2 (hBD2) (ELISA). Comparisons for each type of test were made between skin explants coming from same donor. A difference of IL-8 or hBD2 expression less that 0.01 was considered as significant.

Results: microbial extract of *P. acnes* induced a significant increase of IL-8 expression in all untreated skin explants. Skin explants treated by TLR2-Regul® in contact with microbial extracts had a significant less important expression of IL-8 compared to control ($p<0.01$) (Figure 3).

Skin explants in contact with *P. acnes* pre-treated with TLR2-Regul® had a significant up-regulated expression of hBD2 compared to untreated explants in contact with the same microbial extract ($p<0.01$) (Figure 4).

In these studies on human skin explants previously treated by the TLR2-Regul® and exposed to *P. acnes* extract, the expression of IL-8 was significantly decreased compared to untreated skin ($p<0.01$), antimicrobial peptide hBD2 expression was significantly up-regulated in skin treated with TLR2-Regul® in contact with *P. acnes* compared to untreated skin.

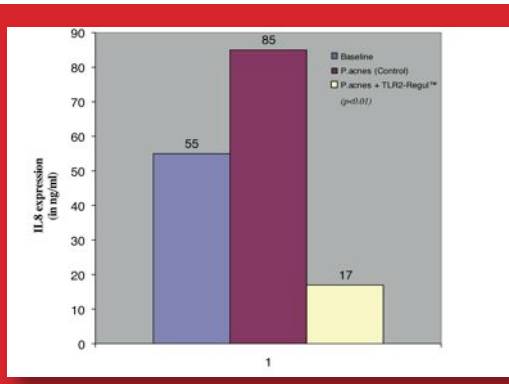

Figure 3. IL-8 release in human skin explants in contact with P. acnes extract.

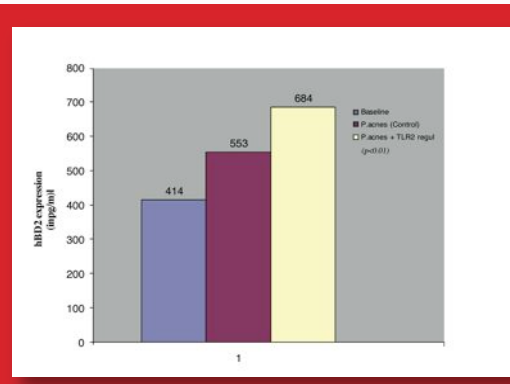

Figure 4. Human beta-defensin 2 (hBD2) expression in human skin explants in contact with P. acnes extract.



Figure 5. O/W emulsion (with 1% TLR2-RegulTM) applied 2X/day in monotherapy in patients with light inflammatory acne (baseline and week 12).

Clinical application of TLR2 modulation in inflammatory acne

The purpose of this *in vivo* pilot study was to assess the effects of TLR2-Regul® in a double blind clinical trial study in patients with light inflammatory acne.

Methods: TLR2-Regul® was included in a formula of an O/W emulsion (at 1%) and tested in monotherapy in acne patients with light inflammatory forms. Were included adult acne patients (above 18 years old) with light inflammatory acne on IGA scale19, rated 2 to 3 on the 5-point investigator global assessment of acne severity scale.

Included patients were randomized and treated with verum or by its excipient. Were excluded patients with IGA scores less than 2 or over 3, patients under topical and/or systemic treatment for acne or having stopped their treatment less than 4 weeks before baseline. Daily cleansers used by the patients during the trial were *"neutral"* (no anti-acne effect).

Results: were included 34 adult acne patients, 16 in the group A (verum) and 18 in group b (excipient), with a mean score of acne IGA score of 2.3 in group A *vs* 2.2 in group B.

Inflammatory lesions decreased significantly at 3 months in the group verum (mean IGA decreased by 40% compared to baseline) compared to its excipient (mean IGA decreased by 24% compared to baseline) ($p>0.05$) (Figure 5). Skin tolerance was very good in both groups.

Conclusions

Human skin explants in contact with *P. acnes* express increased levels of IL-8, in skin explants pre- treated with TLR2-Regul® emulsion the expression of IL-8 was less important compared to control ($p<0.01$). In pre-treated skin with TLR2-Regul® in contact with *P. acnes* the expression of anti- microbial peptide hBD2 was up-regulated. In this double blind, pilot clinical trial in a series of 34 patients with light inflammatory acne (IGA score 2 to 3), the group treated with the emulsion based on TLR2-Regul® showed at week 12 a significant decrease of inflammatory lesions compared to excipient group ($p<0.05$). As a recently developed area of research, the interest for the innate immunity is continuously growing in dermatology, especially with the opening of new and therapeutic prospective targeting TLRs. The development of active ingredients that are able to modulate the innate response can open new ways of treatment in the field of inflammatory skin diseases aggravated by microorganisms as acne. Larger clinical trials are ongoing in order to confirm the results of the pilot trial presented in this article. Most recently, the topical calcineurin antagonists such as tacrolimus [16] and pimecrolimus [17, 18] have been successfully used. Thus, they should be considered as alternative or adjuvant therapies for patients who do not respond to traditional treatment. Otherwise, prevention becomes a priority in the management of SIRD. It may be a recalcitrant problem, imposing a great psychological stress on the patients.

Disclosures:
Studies were supported by Laboratoires Dermatologiques d'Uriage®

References

1. Lemaitre B, Nicolas E, Michaut L, Reichhart JM, Hoffmann JA. The dorsoventral regulatory gene cassette spätzle/Toll/cactus controls the potent antifungal response in Drosophila adults. Cell. 1996; 86(6):973-83.

2. Poltorak A, He X, Smirnova I, Liu MY, Van Huffel C, Du X, Birdwell D, Alejos E, Silva M, Galanos C, Freudenberg M, Ricciardi-Castagnoli P, Layton B, Beutler B. Defective LPS signaling in C3H/HeJ and C57BL/10ScCr mice: mutations in Tlr4 gene. Science. 1998; 282(5396):2085-8.

3. Kang SSW, Kauls LS, Gaspari AA. Toll-like receptors: Applications to dermatologic disease. J Am Acad Dermatol 2006; 54(6):951-83.

4. Musette P, Auquit Auckbur I, Begon E. Innate immunity: cutaneous expression of Toll-like receptors. Med/Sci (Paris) 2006; 22:149-52.

5. Meyer T, Stockfleth E, Christophers E. Immune response profiles in human skin. Br J Dermatol. 2007; 157 Suppl 2:1-7.

6. Wang X, Bi Z, Wang Y, Wang Y. Increased MAPK and NF- B expression of Langerhans cells is dependent on TLR2 and TLR4, and increased IRF-3 expression is partially dependent on TLR4 following UV exposure. Mol Med Report. 2011; 4(3):541-6.

7. Hänsel A, Günther C, Ingwersen J, Starke J, Schmitz M, Bachmann M, et al. Human slan (6-sulfo LacNAc) dendritic cells are inflammatory dermal dendritic cells in psoriasis and drive strong TH17/TH1 T-cell responses. J Allergy Clin Immunol 2011; 127(3):787-94.

8. Schwandner R, Dziarski R, Wesche H, Rothe M, Kirschning CJ. Peptidoglycan- and lipoteichoic acid-induced cell activation is mediated by toll-like receptor 2. J Biol Chem 1999; 274:17406-9.

9. Yang RB, Mark MR, Gurney AL, Godowski PJ. Signaling events induced by lipopolysaccharide- activated toll-like receptor 2. J Immunol 1999; 163:639-43.

10. Nagy I, Pivarcsi A, Koreck A, Széll M, Urbán E, Kemény L. Distinct strains of Propionibacterium acnes induce selective human beta-defensin-2 and interleukin-8 expression in human keratinocytes through toll-like receptors. J Invest Dermatol 2005; 124:931-8.

11. Liu PT, Krutzik SR, Kim J, Modlin RL. Cutting edge: all-trans retinoic acid down-regulates TLR2 expression and function. J Immunol 2005; 174:2467-70.

12. Kurokawa I, Danby FW, Ju Q, Wang X, Xiang LF, Xia L, et al. New developments in our understanding of acne pathogenesis and treatment. Exp Dermatol. 2009;18(10):821-32.

13. Bellew S, Thiboutot D, Del Rosso JQ. Pathogenesis of acne vulgaris: what's new, what's interesting and what may be clinically relevant. J Drugs Dermatol. 2011;10(6):582-5.

14. Harder J, Bartels J, Christophers E, Schröder JM. A peptide antibiotic from human skin. Nature 1997;387:861.

15. O'Neil DA, Porter EM, Elewaut D, Anderson GM, Eckmann L, Ganz T, Kagnoff MF. Expression and regulation of the human beta-defensins hBD-1 and hBD-2 in intestinal epithelium. J Immunol 1999; 163:6718-24.

16. Nakatsuji T, Kao MC, Zhang L, Zouboulis CC, Gallo RL, Huang CM. Sebum free fatty acids enhance the innate immune defense of human sebocytes by upregulating beta-defensin-2 expression. J Invest Dermatol 2010; 130(4):985-94.

17. Ionescu MA, Gougerot A, Matta AM, Lefeuvre L. Toll-like receptor 2 and IL-8 down-regulation in microbial-stimulated human skin explants. J Am Acad Dermatol 2009; 60(3): AB84.

18. Gougerot A, Matta AM, Lefeuvre L. Dermatoses inflammatoires et toll-like récepteurs (TLR). Nouv Dermatol 2009; 28:213-9.

19. Lucky AW, Barber BL, Girman CJ, Williams J, Ratterman J, Waldstreicher J. A multirater validation study to assess the reliability of acne lesion counting. J Am Acad Dermatol. 1996; 35(4):559-65.

EJA
European Journal of Acne and Related Diseases
Volume 2, n. 3, 2011

Elena Guanziroli, Mauro Barbareschi

Department of Anaesthesiology, Intensive Care and Dermatological Sciences, Università degli Studi di Milano, Fondazione IRCCS Ca' Granda Ospedale Maggiore Policlinico, Milan, Italy

Treatment of steroid-induced rosacea-like dermatitis (SIRD)* with azithromycin



Elena Guanziroli

SUMMARY

Steroid-induced rosacea-like dermatitis (SIRD) is a relatively common dermatosis caused by the prolonged and improper application of topical steroids on the face. It mainly involves an adult population and is characterized by an eruption of papules, pustules, papulovesicles, and sometimes nodules with telangiectatic vessels on a diffuse erythematous and edematous background.
There are three types of SIRD that are classified according to localization of the eruption: perioral, centrofacial and diffuse. Diagnosis of this entity is based on patient history and physical examination. Gradual discontinuation of the topical steroid and addition of oral anti-inflammatory antibiotics and/or topical antibiotics are usually recommended to get a good clinical result. Topical tacrolimus or pimecrolimus should be considered as alternative or adjunctive therapies for patients who do not respond to traditional treatments. Clearing of the lesions may take several months.

Key words: Topical corticosteroids, rosacea, steroid dermatitis.

Introduction

Topical glucocorticosteroids were introduced more than 50 years ago and they are the most frequently used drugs in dermatologic practice because of their anti-inflammatory and immunosuppressive action [1].

The most frequent local adverse effects include atrophy, telangiectasia, erythema, papulopustular eruptions, and microbial superinfections.

The excessive, regular use of topical corticosteroids on the face is a common problem, often producing an eruption clinically indistinguishable from rosacea [2]. It is not considered to be a subtype of disease but rather an adverse drug reaction that mimics rosacea. Numerous terms have been used by various Authors to describe this dermatosis such as iatrosacea, steroid-rosacea, steroid dermatitis resembling rosacea, rosacea-like dermatitis and lastly SIRD [3-6].

* *SIRD: Steroid-induced rosacea-like dermatitis.*

Case report

A 37-year-old woman presented with a diffuse papular, erythematous facial dermatitis that had become progressively worse in the last few months.

Her past medical history included epilepsy, for which she was in therapy with phenobarbital (100 mg/day since 2001).

The patient stated that she had used mometasone furoate 0,1% cream once-daily on the face during the preceding 5 years.

The last application had been the evening before she was admitted to our Institute.

She complained of pruritus, dryness and burning sensation.

On clinical examination, she had diffuse papules on a background of erythema localized to the face, extending to the neck (Figure 1).

She had no clinical evidence of conjunctivitis.

Direct microscopic examination did not reveal the presence of Demodex.

We instructed her to discontinue mometasone furoate 0,1% cream and she underwent a treatment with azythromicine (500 mg/day for three consecutive days a week for three months) and desloratadine (5 mg/day for three weeks).
We also recommended local application of emollients and compresses of chamomile and physiological solution. In addition, we explained to the patient that cessation of steroids treatment could be followed by severe rebound erythema, oedema and inflammatory lesions and that eruption could take many weeks to improve. After three months the facial rash significantly improved, although the red papules were still visible (Figure 2).
Two months later an additional improvement of the dermatitis was observed (Figure 3).

Discussion

SIRD is a pruritic, painful, inflammatory process characterized by monomorphic papules and pustules distributed in areas that have been chronically exposed to topical steroids (red face syndrome) [7].
According to localization SIRD is classified in three types: perioral, diffuse and centrofacial.
The perioral type presents discrete to moderate erythema with papules and pustules located around the mouth. In the centrofacial type, the cheeks, lower eyelids, nose, forehead and glabella are affected, while skin in the perioral region is normal. The entire face, forehead and neck are affected in the diffuse type [5].
The subject experiences severe discomfort and pain, including sensations of tightness, moderate burning or stinging, dryness and occasionally intensive pruritus.
The average duration of treatment required to produce adverse effects in most cases is 6 months or more, but it varies and it is also steroid-potency dependent [7].
Althought the risk of SIRD is greater with fluorinated corticosteroids; the prolonged use of non-fluorinated type (such as mometasone furoate) on the face may also reproduce many of the signs and symptoms characteristic of papulopustular rosacea [8].
Most cases of SIRD occur in women between 40 and 50 years old, but also men and even children [9] are affected.
The pathogenesis of this disorder still has to be clarified.
Leyden et al. [10] in their original description of steroid-induced rosacea, suggested that these patients may be predisposed to the development of rosacea and this is unmasked by the topical steroid.
An accumulation of various metabolites such as nitric oxide and the overgrowth of microorganism (which is facilitated by the immunosuppressive properties of steroids) might be implicated.
Demodex folliculorum may have a pathogenic role only when present in high density, causing inflammation or allergic reaction or acting as vector for other microorganisms [11].
Anamnestic data, revealing prolonged use of local corticosteroids, associated with a characteristic clinical picture are indicative for diagnosis.
The differential diagnosis includes acne, rosacea, seborrhoeic dermatitis, perioral dermatitis, irritant contact dermatitis, photosensitive dermatitis, systemic lupus erythematosus and dermatomyositis [12].
Withdrawal of topical steroid is essential, but this usually leads to relapse of the eruption. To prevent this, some authors have suggested mild topical steroids, such as hydrocortisone, which cuts down the violence of the rebound reaction, while allowing the atrophic collagen to recover [13].
Other authors taper the dose of topical corticosteroids by reducing the frequency of application [14].
In severe cases, oral anti-inflammatory antibiotics (tetracycline or macrolides), with or without topical antimicrobial therapy (erythromycin, metronidazole or clindamycin), need to be added to the treatment regimen [15].
Most recently, the topical calcineurin antagonists such as tacrolimus [16] and pimecrolimus [17, 18] have been successfully used.
Thus, they should be considered as alternative or adjuvant therapies for patients who do not respond to traditional treatment.
Otherwise, prevention becomes a priority in the management of SIRD. It may be a recalcitrant problem, imposing a great psychological stress on the patients.



Figure 1.
SIRD: diffuse type.



Figure 2.
Clinical aspect after antibiotic therapy.



Figure 3.
Improvement of the face lesions after 5 months of follow-up.

References

1. Brazzini B, Pimpinelli N. New and established topical corticosteroids in dermatology: clinical pharmacology and therapeutic use. Am J Clin Dermatol 2002; 3:47-58.

2. Hengge UR, Ruzicka T, Schwartz RA, Cork MJ. Adverse effects of topical glucocorticosteroids. J Am Acad Dermatol 2006; 54:1-15.

3. Hornstein OP. Perioral (rosaceiform) dermatitis - a 'modern' problem disease. Internist 1975; 16:27-8.

4. Litt JZ. Steroid-induced rosacea. Am Fam Physician 1993; 48:67-71.

5. Ljubojeviae S, Basta-Juzbasiae A, Lipozenèiae J. Steroid dermatitis resembling rosacea: aetiopathogenesis and treatment. J Eur Acad Dermatol Venereol 2002; 16:121-6.

6. Chen AY, Zirwas MJ. Steroid-induced rosacealike dermatitis: case report and review of the literature. Cutis 2009; 83:198-204.

7. Bhat YJ, Manzoor S, Qayoom S. Steroid-induced rosacea: a clinical study of 200 patients. Indian J Dermatol 2011; 56:30-2.

8. Prakash A, Benfield P. Topical mometasone. A review of its pharmacological properties and therapeutic use in the treatment of dermatological disorders. Drugs 1998; 55:145-63.

9. Weston WL, Morelli JG. Steroid rosacea in prepubertal children. Arch Pediatr Adolesc Med 2000; 154:62-4.

10. Leyden JJ, Thew M, Kligman AM. Steroid rosacea. Arch Dermatol 1974; 110:619-22.

11. Basta-Juzbasić A, Subić JS, Ljubojević S. Demodex folliculorum in development of dermatitis rosaceiformis steroidica and rosacea-related diseases. Clin Dermatol 2002; 20:135-40.

12. Lu H, Xiao T, Lu B, et al. Facial corticosteroid addictive dermatitis in Guiyang City, China. Clin Exp Dermatol 2010; 35:618-21.

13. Sneddon IB. The treatment of steroid-induced rosacea and perioral dermatitis. Dermatologica 1976; 152: 231-7.

14. Bikowski JB. Topical therapy for perioral dermatitis. Cutis 1983; 31: 678-82.

15. Rathi SK, Kumrah L. Topical corticosteroid-induced rosacea-like dermatitis: a clinical study of 110 cases. Indian J Dermatol Venereol Leprol 2011; 77:42-6.

16. Goldman D. Tacrolimus ointment for the treatment of steroid-induced rosacea: a preliminary report. J Am Acad Dermatol 2001; 44:995-8.

17. Chu CY. An open-label pilot study to evaluate the safety and efficacy of topically applied pimecrolimus cream for the treatment of steroid-induced rosacea-like eruption. J Eur Acad Dermatol Venereol 2007; 21:484-90.

18. Lee DH, Li K, Suh DH. Pimecrolimus 1% cream for the treatment of steroid-induced rosacea: an 8-week split-face clinical trial.Br J Dermatol 2008; 158:1069-76.

EJA
European Journal of Acne and Related Diseases
Volume 2, n. 3, 2011

Stefano Veraldi, Rossana Schianchi*

Department of Anaesthesiology, Intensive Care and Dermatological Sciences, University of Milan, I.R.C.C.S. Foundation, Ca' Granda Ospedale Maggiore Policlinico, Milan, Italy

**European Institute of Dermatology, Milan, Italy*

Short contact therapy of acne with tretinoin



Stefano Veraldi

SUMMARY

Forty-three patients with mild to moderate acne were treated with 0.05% tretinoin cream. The latter was applied once daily, in the evening, for 30 minutes ("short contact therapy" modality). The application was preceded and followed by a cleaning. No other topical and/or systemic products or drugs were allowed, except for sunscreens. In particular, moisturizers were not allowed. Treatment duration ranged from 8 to 32 weeks (mean duration: 12 weeks). Acne severity and treatment efficacy were evaluated by means of the Global Acne Grading System (GAGS). Significant clinical improvement was judged as ≥ 50% improvement from baseline. A significant improvement was observed in 26 out of 43 patients (60.5%). Nine out of 43 patients (20.9%) developed a mild tretinoin-induced dermatitis. In one patient (2.3%) dermatitis was judged as severe and the patient stopped the treatment. On the basis of the results of this study, short contact therapy with 0.05% tretinoin cream is effective and very well tolerated in mild to moderate acne.

Key words: Acne, irritant contact dermatitis, retinoid dermatitis, retinoids, short contact therapy, tretinoin.

Introduction

We present the preliminary results of a sponsor-free, pilot, open, multicenter study for the evaluation of activity and tolerability of 0.05% tretinoin cream, used as short contact therapy (SCT), in the treatment of mild to moderate acne.

Patients and methods

Forty-three Caucasian patients [24 males (55.8%) and 19 females (44.2%)], with an age ranging from 14 to 36 years (mean age: 21.7 years), with mild to moderate acne, were treated with 0.05% tretinoin cream. The latter was applied, after a wash out period of at least two weeks, once daily, in the evening, for 30 minutes. The application was preceded and followed by a cleaning. No other topical and/or systemic products or drugs were allowed, except for sunscreens. In particular, moisturizers were not allowed. Treatment duration ranged from 8 to 32 weeks (mean duration: 12 weeks). All patients were clinically evaluated every 6±2 weeks. Acne severity and treatment efficacy were evaluated by means of the *Global Acne Grading System* (GAGS) [1]. Significant clinical improvement was judged as an improvement ≥50% from baseline.

Results

A significant improvement was observed in 26 out of 43 patients (60.5%). Nine out of 43 patients (20.9%) developed a mild tretinoin-induced dermatitis. In one out of 43 patients (2.3%) dermatitis was judged as severe: the patient stopped the treatment.

Discussion

The most frequent side effect of topical retinoids is represented by an irritant contact der-

matitis, commonly named retinoid dermatitis (RD) [2]. This dermatitis is characterized clinically by the more or less acute appearance of signs (dryness, erythema, scaling and oedema) and symptoms (burning and itching). Dryness, erythema and burning are the three more frequent features, whereas scaling, itching and oedema are rare. RD is very common, occurring in approximately 85% of patients; in patients treated with tretinoin, the percentage can reach up to 95% of patients. Furthermore, RD would be more frequent in patients with low phototypes. According to the pathogenetic point of view, RD is mediated by pro-inflammatory cytokines, such as interleukin (IL) 1, IL 1α, IL 8 and tumor necrosis factor α.

RD usually appears following the first applications of the retinoid. Very rarely RD persists for all the duration of the treatment. Severity of RD is due to the type of retinoid: retinol and retinaldehyde are not irritant, while tretinoin and tazarotene can be very irritant (Table 1) [3].

Table 1.
Topical retinoids and severity of irritant contact dermatitis [3] (modified)

	Dryness	Erythema	Burning
Retinol	-	-	-
Tretinoin	+++	+++	++
Isotretinoin	++	++	+
Adapalene	+	+	+
Retinaldehyde	-	-	-
Tazarotene	+++	+++	+++

Moreover, dermatitis severity is concentration-dependent and due to the vehicle used: more irritant are those retinoids in alcoholic gels.

In its entirety, severity of RD is mild to moderate and duration is changeable, from a few days up to three weeks. However, in our clinical experience, severity of tretinoin-induced dermatitis is moderate to severe in approximately 15% of patients. Furthermore, always in our experience, 12 to 15% of patients stop the treatment. RD improves after treatment suspension or by application of moisturizers or, in more severe cases, of low- to mid-potency corticosteroids.

Prevention of RD is based on the following items:

a) to begin the treatment with lower concentrations of retinoid, if possible;
b) to begin the treatment applying the retinoid every two days;
c) to associate, from the beginning of the treatment, a moisturizer.

On the basis of our previous experiences about the use of tazarotene as SCT in psoriasis [4, 5] we evaluated the possibility to use tretinoin as SCT in acne. To our knowledge, tretinoin was used as SCT only in diabetic patients with chronic ulcers of the foot in order to stimulate granulation tissue [6, 7]. Results of our study (open, although sponsor-free, multicentre and based on a high number of evaluable patients) may be summarized as follows:

a) clinical activity of tretinoin used as SCT seems to be superimposable to that of tretinoin used according to standard modality;
b) tolerability of SCT with tretinoin is very good: as previously mentioned, only 9 out of 43 patients (20.9%) developed a dermatitis and in only one patient (2.3%) dermatitis was judged as severe, for which the patient stopped the treatment.

The good tolerability allows a high adherence of patients, mainly young patients, to the treatment: SCT with tretinoin markedly improves compliance. A controlled clinical study, in order to confirm these results, is mandatory.

References

1. Doshi A, Zaheer A, Stiller MJ. A comparison of current acne grading systems and proposal of a novel system. Int J Dermatol 1997; 36:416-8.

2. Cunliffe WJ. Acne. Martin Dunitz, Londra, 1994; 242.

3. Cunliffe WJ, Gollnick HPM. Acne. Diagnosis and management. Martin Dunitz, Londra, 2001; 110.

4. Veraldi S, Schianchi R. Short-contact therapy with tazarotene in psoriasis vulgari. Dermatology 2003; 206:347.

5. Veraldi S, Caputo R, Pacifico A, Peris K, Soda R, Chimenti S. Short-contact therapy with tazarotene in psoriasis vulgaris. Dermatology 2006; 212:235.

6. Paquette D, Badiavas E, Falanga V. Short-contact topical tretinoin therapy to stimulate granulation tissue in chronic wounds. J Am Acad Dermatol 2001; 45:382-6.

7. Tom WL, Peng DH, Allaei A, Hsu D, Hata TR. The effect of short-contact topical tretinoin therapy for foot ulcers in patients with diabetes. Arch Dermatol 2005; 141:1373-7.